



## The lungs, airspaces, and interstitium

The lungs—easily missed pathology

---

---

---

---

---

### What will I gain from this video?

After watching this video, you will have acquired an approach to minimizing the number of overlooked lung lesions.

---

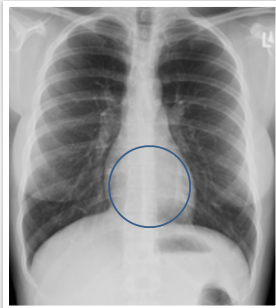---

---

---

---

### Retrocardiac region on PA



---

---

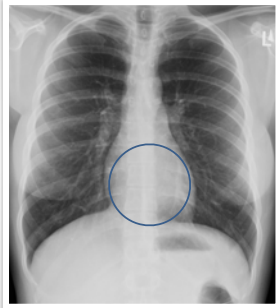---

---

---

**Retrocardiac region  
on PA**

Obscured by heart



---

---

---

---

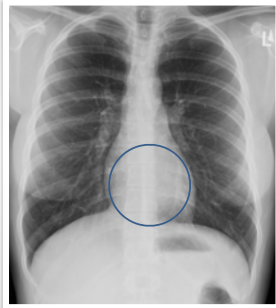
---

---

**Retrocardiac region  
on PA**

Obscured by heart

Recommendation:



---

---

---

---

---

---

**Retrocardiac region  
on PA**

Obscured by heart

Recommendation:

1. Scan this region



---

---

---

---

---

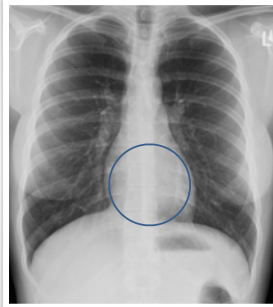
---

**Retrocardiac region  
on PA**

Obscured by heart

Recommendation:

1. Scan this region
2. Look at lateral



---

---

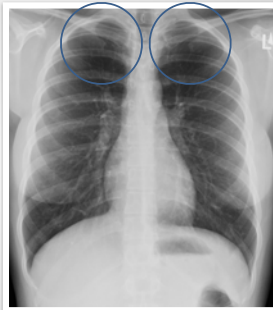
---

---

---

---

**Apices on PA**



---

---

---

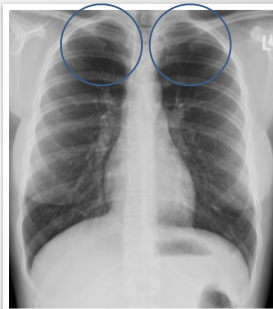---

---

---

**Apices on PA**

Obscured by ribs and clavicles



---

---

---

---

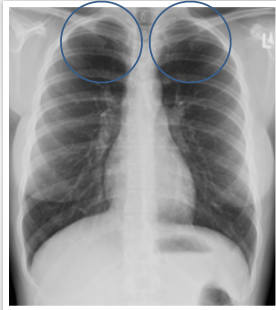
---

---

### Apices on PA

Obscured by ribs and clavicles

Recommendation:



---

---

---

---

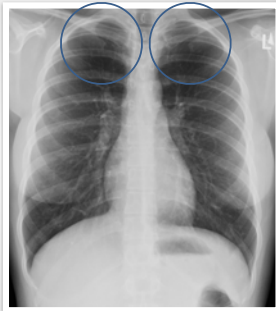
---

### Apices on PA

Obscured by ribs and clavicles

Recommendation:

1. Scan this region



---

---

---

---

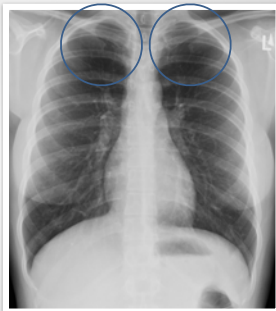
---

### Apices on PA

Obscured by ribs and clavicles

Recommendation:

1. Scan this region
2. Compare sides



---

---

---

---

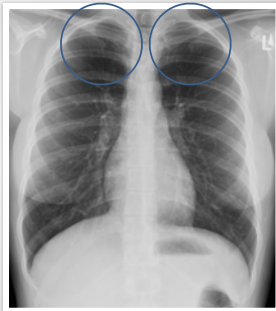
---

### Apices on PA

Obscured by ribs and clavicles

Recommendation:

1. Scan this region
2. Compare sides
3. May need lordotic view



---

---

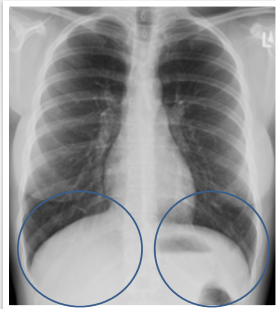
---

---

---

---

### Lower diaphragms on PA



---

---

---

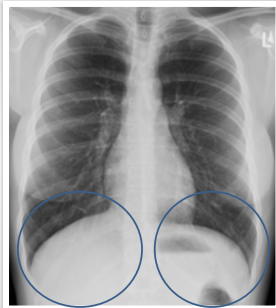
---

---

---

### Lower diaphragms on PA

Obscured by diaphragms and liver/spleen



---

---

---

---

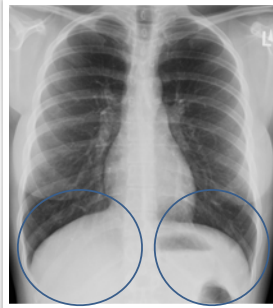
---

---

**Lower diaphragms on PA**

Obscured by diaphragms and liver/spleen

Recommendation:



---

---

---

---

---

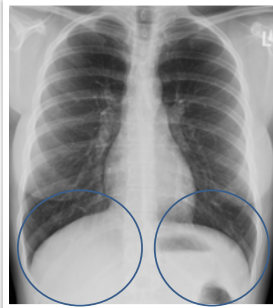
---

**Lower diaphragms on PA**

Obscured by diaphragms and liver/spleen

Recommendation:

1. Scan this region



---

---

---

---

---

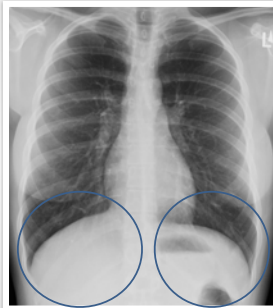
---

**Lower diaphragms on PA**

Obscured by diaphragms and liver/spleen

Recommendation:

1. Scan this region
2. Compare sides



---

---

---

---

---

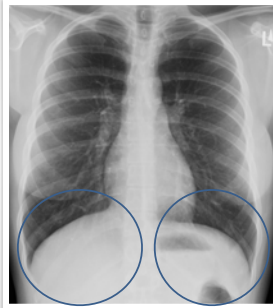
---

### Lower diaphragms on PA

Obscured by diaphragms and liver/spleen

Recommendation:

1. Scan this region
2. Compare sides
3. Look at lateral



---

---

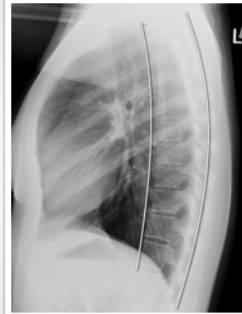---

---

---

---

### Overlying the spine on LATERAL



---

---

---

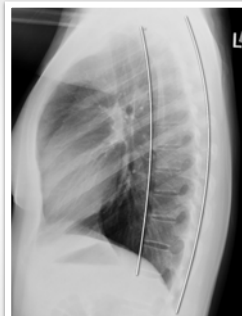---

---

---

### Overlying the spine on LATERAL

Obscured by vertebral bodies and soft tissues



---

---

---

---

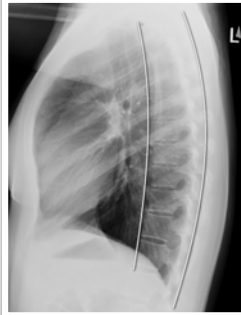---

---

**Overlying the spine  
on LATERAL**

Obscured by vertebral bodies and  
soft tissues

Recommendation:



---

---

---

---

---

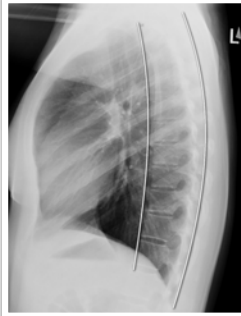---

**Overlying the spine  
on LATERAL**

Obscured by vertebral bodies and  
soft tissues

Recommendation:

1. Scan this region



---

---

---

---

---

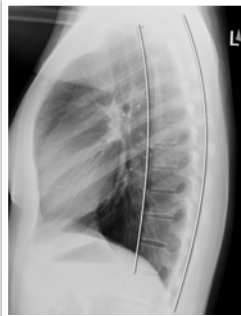
---

**Overlying the spine  
on LATERAL**

Obscured by vertebral bodies and  
soft tissues

Recommendation:

1. Scan this region
2. Should get darker inferiorly



---

---

---

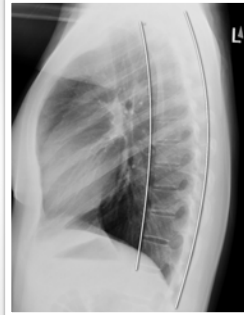---

---

---



**Retrosternal space  
on LATERAL**



---

---

---

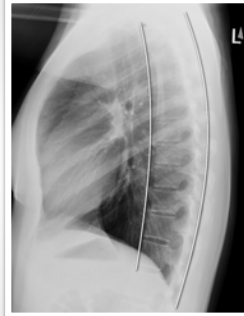---

---

---

**Retrosternal space  
on LATERAL**

Obscured by upper extremities



---

---

---

---

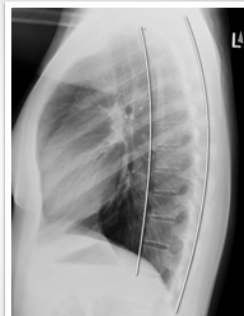---

---

**Retrosternal space  
on LATERAL**

Obscured by upper extremities

Recommendation:



---

---

---

---

---

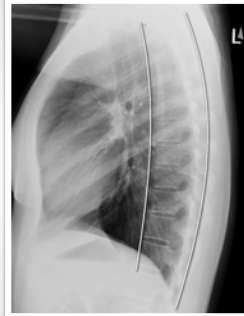---

### Retrosternal space on LATERAL

Obscured by upper extremities

Recommendation:

1. Scan this region



---

---

---

---

---

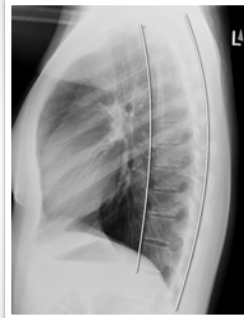---

### Retrosternal space on LATERAL

Obscured by upper extremities

Recommendation:

1. Scan this region
2. Look at PA



---

---

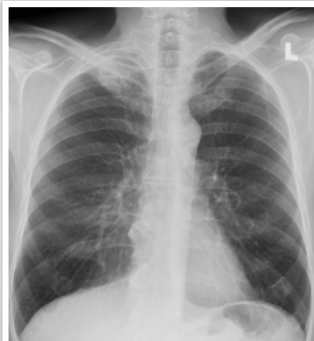---

---

---

---

### Example case 1



---

---

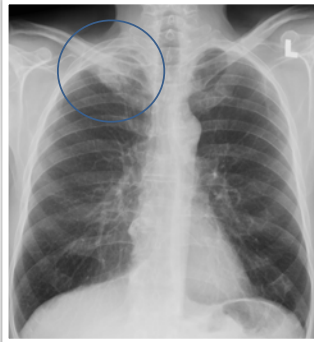
---

---

---

---

Example case 1



---

---

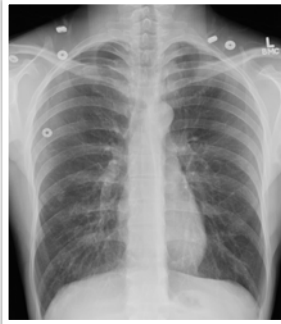
---

---

---

---

Example case 2



---

---

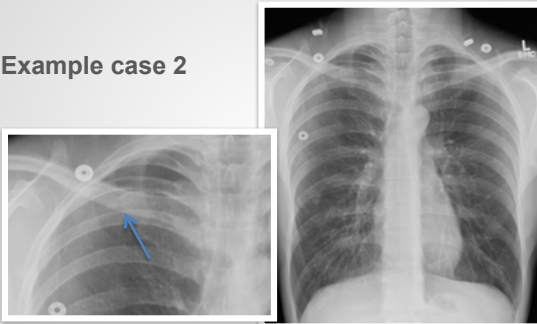---

---

---

---

Example case 2



---

---

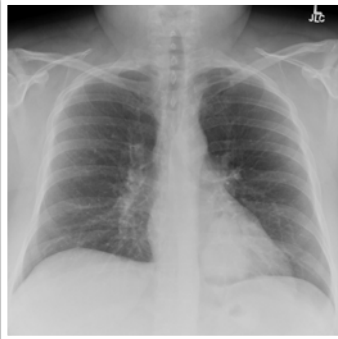---

---

---

---

**Example case 3**



---

---

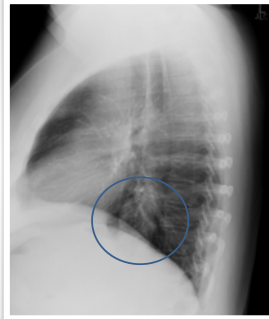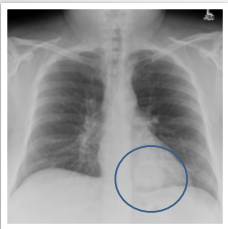
---

---

---

---

**Example case 3**



---

---

---

---

---

---

**Where to look to minimize missing lesions**

**On PA**

- Behind the heart
- Below diaphragms
- Apices

---

---

---

---

---

---

### Where to look to minimize missing lesions

#### On PA

- Behind the heart
- Below diaphragms
- Apices

#### On lateral

- Apices
- Retrosternal air space
- Over the spine

### Where to look to minimize missing lesions

#### On PA

- Behind the heart
- Below diaphragms
- Apices

#### On lateral

- Apices
- Retrosternal air space
- Over the spine

#### Watch out for artifacts!

Know the limitations of a poor quality examination